

Full-Mouth Restoration With TMJ Involvement: *A Case Report*

By Raymond J. Voller, DMD

Full-mouth restoration is a major challenge to the competence and confidence of dental practitioners. The difficulty of the technique required to achieve a harmonious restoration of one central incisor is multiplied in a complete reconstruction. To achieve a satisfactory result, reinstatement of form, function, and aesthetics is paramount. It is important to understand the teamwork and communication required of the dentist, patient, staff, and laboratory technician in such complex cases. If the role of each team member is determined at the treatment planning stage and implemented subsequently, the result will be aesthetically and functionally acceptable.

CASE STUDY

A 45-year-old male, referred by a periodontist, presented with unsatisfactory dental restorations, a chronic dysfunction of temporomandibular joints (TMJs), and assorted occluso-muscular pain. The patient acknowledged a severe clenching and bruxing habit, resulting from a stressful work environment. Several clinicians had attempted to treat the dysfunction by equilibration but without success. In the process, the vertical dimension of the

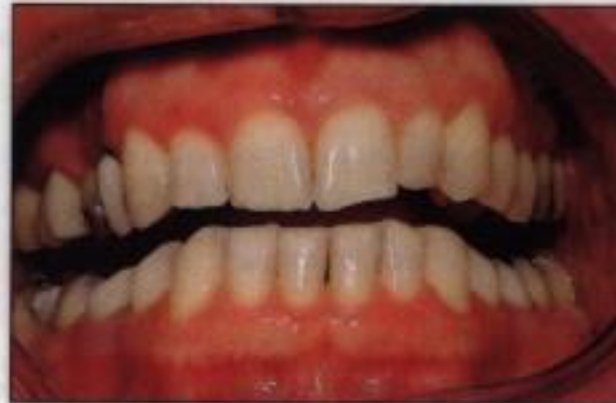

Figure 1. Preoperative retracted facial view illustrating uneven occlusal plane and gull wing appearance of dentition.

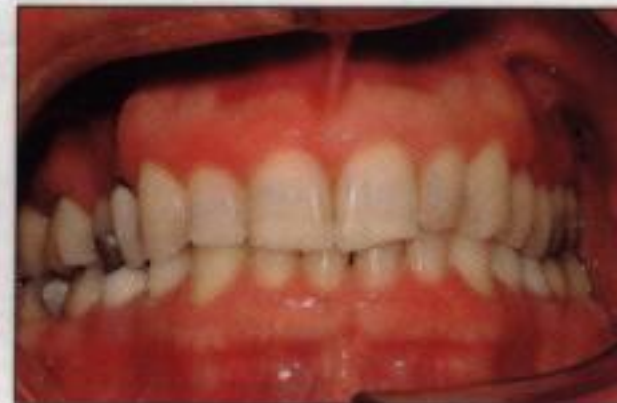

Figure 2. Preoperative facial view of the dentition in maximum intercuspation position.

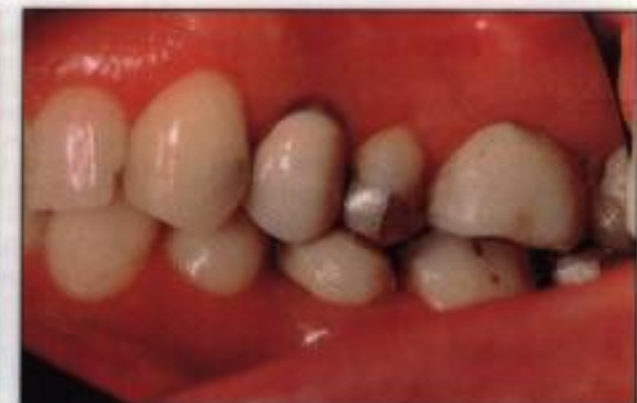

Figure 3. Preoperative right posterior lateral view of occlusion.

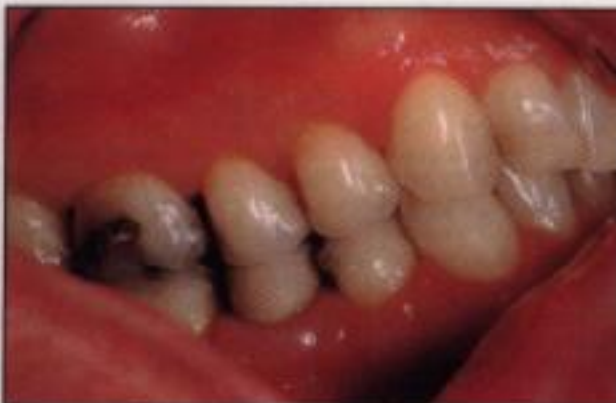

Figure 4. Preoperative left posterior lateral view of occlusion.

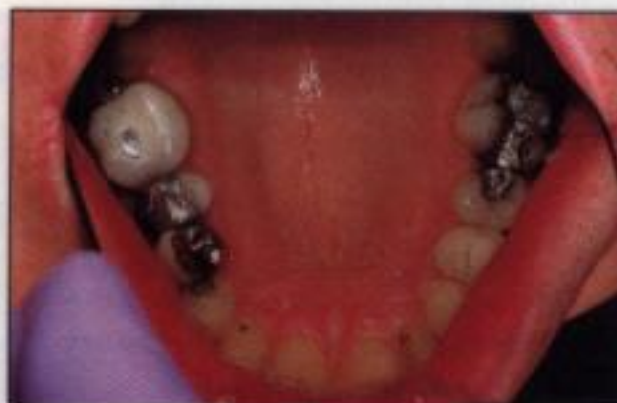

Figure 5. Preoperative occlusal view of the maxillary dentition.

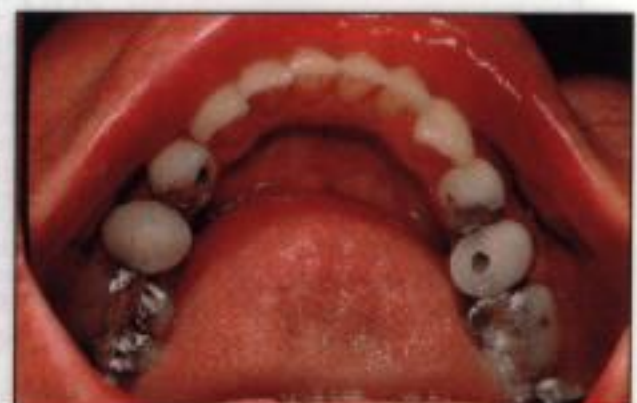


Figure 6. Preoperative facial view of mandibular dentition illustrating wear.

